

# Automated Detection of Neovascular Glaucoma through Fractal Dimension Method

Dharmanna Lamani<sup>1</sup>, Dr. T. C. Manjunath<sup>2</sup>, Dr. U P Kulkarni<sup>3</sup>

<sup>1</sup>Assistant Professor, CSE, Dept, SDMIT Ujire, India

<sup>2</sup>Principal, HKBK college of Engineering Bangalore, India

<sup>3</sup>Professor, Computer Science & Engg, Department, SDMCET, Dharwad, India

**Abstract:** This paper investigates the development of digital image analysis method for diagnosing neovascular glaucoma. The conventional ophthalmologist approach attracts some drawbacks such as lot of human involvement that leads to inaccuracy, time consuming and chances of creeping of human errors. Hence to avoid above mentioned drawbacks, this research work is undertaken to diagnose neovascular glaucoma by using image feature namely Fractal Dimension (FD). Fractal dimension found for the healthy retinopathy in the range of 0.98 to 1.61 where as for neovascular glaucoma above 1.61 to 1.99. the results of present work emphasizes that there is a great potential in the use of fractal dimension for diagnosing neovascular glaucoma for ophthalmologist with very minimum manual error. The final results of this research work will contribute to make retinal image properties computation automatic which will help to ophthalmology doctors in healthy and unhealthy retinal image classification.

**Keywords:** Box Counting Method, Neovascular Glaucoma, Fractal Dimension, Diabetes.

## INTRODUCTION

### (A) Neovascular Glaucoma

Neovascular Glaucoma (NVG) is the word literally means building new vessels which causes ocular disorders. NVG is the severe state of glaucoma which may lead to permanent loss of vision if not treated. Weiss and colleagues gave this name for the first time in 1963. This is caused due to the insufficient pumping of oxygen and glucose to the retina. As the result body starts building new blood vessels in wrong place (anterior chamber angle) to keep the tissues alive. These new blood vessels block the aqueous outflow and the new vessels are accompanied by fibrous membrane which on contradiction may result in peripheral anterior synechiae and progressive angle closure. This increases the pressure in eyes which may lead to blindness. The ocular diseases like neovascularisation of iris (NVI) or neovascularisation of angle may finally lead to neovascular glaucoma. The patients suffering from the diseases given below are more prone to NVG.

1. Diabetes Mellitus: The occurrence of NVG is more in diabetic patients. Though the exact percentage is not known, older patients are more prone to NVG than juvenile patients. The risk is more in the patients who have undergone vitrectomy and lensectomy. The blood flow is less in diabetic patients which may cause NVG.

2. Central retinal vein occlusion: The patients suffering from Central retinal vein occlusion are more prone to NVG. There are two types of CRVO ischemic and nonischemic. NVG is less in nonischemic variant. But case study says nonischemic may turn into ischemic CRVO. The patient should be treated or else the patient may develop NVG.
3. Carotid artery obstructive disease: Carotid arteries are arteries that supply blood to brain. The major cause for this is hardening of the arteries in some body parts. The patient suffering from this may not show any sign of developing NVG. The patient's IOP may be low even if the patient has already developed NVA and NVI. If the patient is not treated in time, it may lead to transient ischemic attack or severe stroke.

### (B) Treatment

First step of the treatment is to reduce the IOP in the eyes to lessen the damage caused to optic nerve. Initially, the patient should be given medication to reduce the flow of aqueous humor into the eye. Then drops, beta-blocking agents and pills like acetazolamide are given to further reduce IOP.

Second step is to eradicate neovascularization and take care of the eye. This is possible if the glaucoma is detected at an early stage, when the drain is not completely blocked. In this stage if the neovascularization is removed, the trabecular meshwork is preserved and eye pressure can also be maintained. The neovascularization can be destroyed by eliminating the structures in the retina which reduces blood flow. This also eliminates the chances of building new blood vessels in front of the eye. Various surgeries are done like retinal photocoagulation, cyclodestruction, aqueous drainage implants, etc. Neovascular glaucoma can become severe if the IOP is not reduced. Even though technology is advancing each day there's no suitable treatment for NVG. Hence early detection of NVG is very important. In this research work NVG was detected through fractal dimension method. Authors has described in detail about fractal dimension in the section 2. Figure1 depicts the left retina is healthy and right retina is neovascular.

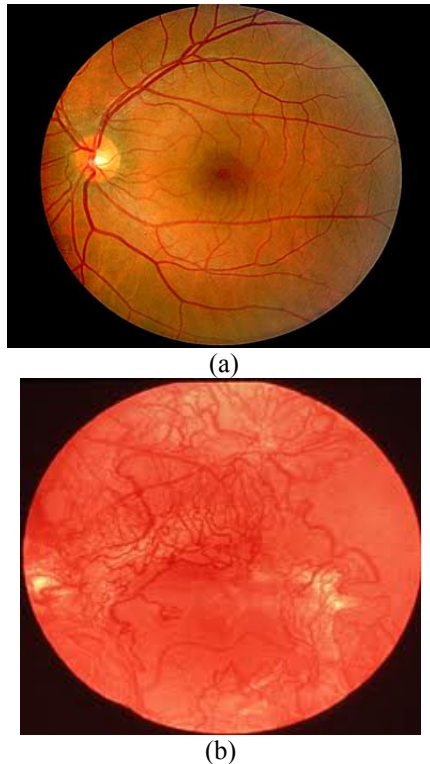


Figure 1. Images of (a) Healthy Retina and (b) Neovascular Retina

M. Z. Che Azemin et al. [21] developed a robust method to perform retinal vascular fractal analysis from digital retina images. To enhance the retinal images, the green channel retina, an image with Gabor wavelet transforms was used. Fourier Fractal dimension is computed on these pre-processed images and does not require any segmentation of the vessels. The repeatability of the proposed method was found to be better than the earlier box-counting method. Using this method to assess retinal vascular fractals resulted in reduction in the retinal vasculature complexity with aging.

Ştefan Talu [22] describes different automated methods in modern ophthalmology, to describe the morphology of human retinal vessel network in fundus eye images. The quantification methods were: vessels morphology analysis based on the measurement of tortuosity, width, branching angle, branching coefficient, fractal dimension and of multifractal spectra. Author reported that the retinal eye images obtained by color fundus imaging may be utilized for the computer-aided diagnosis using the automated analysis methods.

Nilanjan Dey, Anamitra Bardhan Roy, Moumita Pal and Achintya Das [23] proposed an algorithm for segmentation of blood vessels, and compare the results between expert ophthalmologists' hand-drawn ground-truths and segmented image. Hand drawn 'ground-truth' and fuzzy segmented retinal blood vessel that appears split into two parts, i.e. thick and thin vessels according to the contrast were considered in the presented work. Thick vessels were detected by adaptive local thresholding in normalized images, segmentation was done based on the *Fuzzy C-Means (FCM)*.

Ana Salazar-Gonzalez, Djibril Kaba, Yongmin Li and Xiaohui Liu [24] presented a novel method to segment blood vessels and optic disc in the fundus retinal images.

The method could be used to support non-intrusive diagnosis in modern ophthalmology since the morphology of the blood vessel and the optic disc is an important indicator for diseases like diabetic retinopathy, glaucoma and hypertension. First the retina vascular tree was extracted using the graph cut technique, the blood vessel information was then used to estimate the location of the optic disc. optic disc segmentation was performed using two alternative methods. The Markov Random Field (MRF) image reconstruction method segments the optic disc by removing vessels from the optic disc region and the Compensation Factor method segments the optic disc using prior local intensity knowledge of the vessels.

Teruhiko Hamanaka [25] conducted an experiment to evaluate The risk factors for pan-retinal photocoagulation (PRP) failure and the efficacy of achieving a PRP burn density of  $\geq 40\%$  in the mid-periphery against diabetic neovascular glaucoma (NVG). The results showed that Eyes with RP density of less than 40% may have a risk for later development of NVG. The prompt initiation of PRP, a PRP burn density of greater than 40%, and the completion of PRP within 6 months are strongly recommended for the treatment of NVG. Special care should be taken in NVG-affected eyes with small pupils, preexisting glaucoma or OH, or persistent NVD as well as those that are subjected to PRP for more than 12 months.

## 2. METHODOLOGY

Figur2 depicts data flow diagram of methodology adopted in this research work. Data flow diagram divided into six stages. The first stage is input stage; in this stage healthy and neovascular retinal images are provided as a input to experiment. The second stage is conversion stage; in this stage input images are converted RGB image into grayscale scale image using `rgb2gray` matlab function in order to further process. Third stage is normalization stage; in this stage grayscale images are de-noised it means retinal images were enhanced through image normalization function. The fourth stage is resizing stage; each retinal image is resized into power of 2 (i.e. 256X256). In the fifth stage Box Counting Method (BCM) applied in order extract the feature. Final stage is referred as output stage which describes the retina affected by NVG or not.

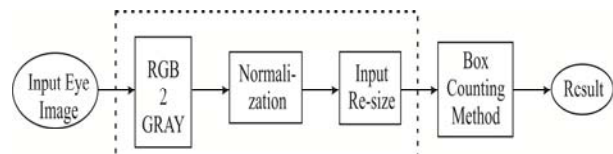


Figure 2. Dataflow Diagram

### (A) Material used.

The fundus images were collected from the Shri Dharmasthala Manjunatheshwara Hospital Dharwad (SDMHD), Karnataka, India. All the images were captured with a high resolution of 530 X 720 pixels. For experiment we have used 25 retinal images: 15 non-glaucoma and 12 neo-vascular glaucoma images from 25-to-56 years old people. The doctors in the Ophthalmology department of the hospital certified the image quality and usability. Fig.

1(a) & 1(b) represents the typical healthy (non-glaucoma) and neo-vascular glaucoma retinal images respectively. The fundus camera with microscope and light source were adopted to capture the retinal images in order to diagnose glaucoma, neovascular glaucoma, macular degeneration, diabetes, etc.

*(B) Image pre-processing*

Image pre-processing can significantly increase the reliability of a small neighborhood of a pixel in an input (I/p) image to get a new brightness value in the output (O/P) image. Such image pre-processing step consists of image using normalization operator. Image normalization significantly increases the dynamic range of the histogram of the image. The intensity value in an input image includes a uniform distribution of intensity. As a result, the contrast of the image was increased. In second pre-processing step neovascular glaucoma images were redder as compared to normal compared to healthy retina. Hence we highlighted red channel component image for the computation of the fractal dimension.

*(C) Extracting image features*

The extraction of image feature is explained through the flow chart shown in Figure 3.




Figure3. Flow chart for Extraction of Image Feature

*(D) Fractal dimension*

Fractal dimension allows us to measure the complexity of an object, that too preferably self similarity such as eye, brain, tree, mountain and so on so forth. Recently Hsiao-Wen Chung et al presented fractal analysis approach for Nuclear medicine images for the diagnosis of Pulmonary Emphysema and concluded that FD seems to be an over simplified parameter unrelated to spatial heterogeneity of images [18]. Fractal analysis is potentially suitable for an objective quantification of spatial heterogeneity because it is believed to be effective in helping to characterize complex system that are hard to describe using conventional Euclidean geometry. Fractal dimension is parameter that can be determined solely by the image intensity [16].

*(E) Box Counting Method (BCM)*

The box counting method is one of the most popular algorithms for determining the fractal dimension of an image. Box counting method is described with following examples. The image was resized to the gray scale image was converted into binary image by bw method later to create square boxes, binary image was resized to a nxn so that the length, measured in number of pixels of a power of 2 this helps for the square image to be equally divided in to four sub parts and again each subparts divided in to four subparts and so on. The number of pixel which contains “white” pixels was recorded as function of the box size N(s), length of box. The reciprocal of box size is also noted as 1/r, this principle is repeated for all the binary images obtained by different threshold values ranging from 0.2 to 0.5 with interval 0.1 of an average binary retinal image. From figure 4, Number of boxes N(s)=4 number of boxes which contains ones N (1/s)=3. Hence fractal dimension = 1.26.

$$FD = \frac{\log(4)}{\log(\frac{1}{3})} = 1.26$$

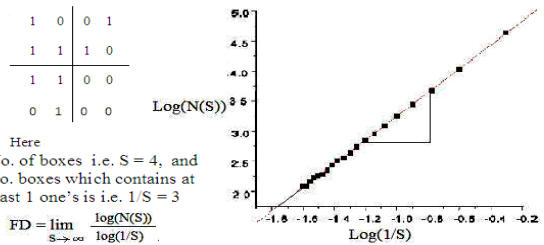


Figure4. Box Counting Method (BCM) Principle

*(F) Algorithm for box counting method*

The box-counting method was used on retinal images to exhibit a fractal structure. The image was resized to measure (256 × 256) and then converted into gray scale. Grayscale images became binary images with a threshold of 0.2 to 0.5 with distance of 0.1, meaning that if the pixel had a binary value greater than threshold (on a 0 to 1 scale) the pixel became “black”, or assigned the value of 0, otherwise if the pixel becomes ‘white’, then a value of 1 is assigned. The Algorithm developed for the box counting method as given below.

```

For each binary image
  Divide the binary image into boxes of size r x r
  For each box of size r
    Count the occupied boxes:N
    Calculate the magnitude factor (1/r)
  End for
End for
FD = log (N) / log (1/r)
    
```

III. EXPERIMENTAL RESULTS

Matlab code was written for a series of original Non-glaucoma and Neo-vascular glaucoma input images (numbering 27) and converted into binary images of size (256 × 256). Different thresholds were considered ranging from 0.2 to 0.5. The code was simulated & run. The output observed is a binary image which is converted from

the gray scale image as shown in the Fig. 12 (a)-(i). The written code computes the FD value for the binary image & the values are shown in the table 1. A series of steps are involved in arriving at the output image after the end of the simulation, viz., (1) given input image (2) computed red channel (3) Separated the red channel from the 3D image and convert it to a 2D image. (4) Computed histogram and (5) Estimated fractal dimension. The proposed algorithm is applied for a set of 22 images which may be affected with Neo-vascular glaucoma or may not be affected & the end result was tabulated. It was observed that out of 22 images,

10 were affected with neo-vascular glaucoma & 12 were not affected with glaucoma, thus serving our end result, i.e., the efficient identification & detection of glaucoma. The quantitative results are tabulated as shown in the table 1 one, for Neo-vascular glaucoma (NVG) & the other for non-glaucoma affected image output. For non-glaucoma images, FD was found in the range of 1.06 to 1.61, whereas for neo-vascular glaucoma FD was found to be above 1.61. The mean & SD was also computed & shown in the table 1.

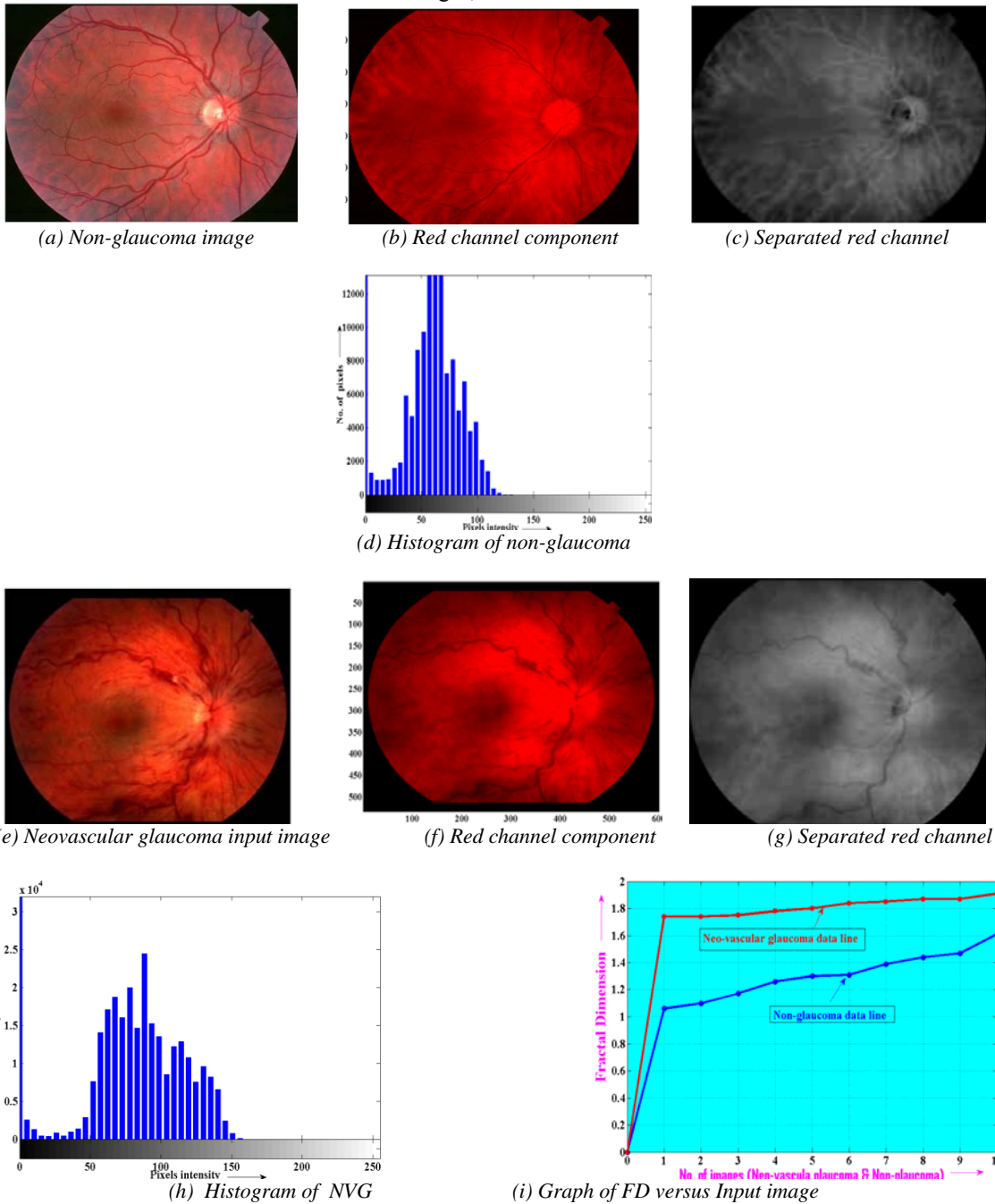


Figure 4: Simulation results of non-glaucoma & Neo-vascular glaucoma affected images

TABLE 1 : STATISTICAL ANALYSIS OF RETINAL IMAGES USING BOX COUNTING METHOD

SL.No.	Non-glaucoma image		Glaucoma image	
	Image Id	FD	Image id	FD
1.	Non-G1001	1.06	Glaucoma-1001	1.74,
2.	Non-G1002	1.17	Glaucoma-1002	1.75
3.	Non-G1003	1.26	Glaucoma-1003	1.84
4.	Non-G1004	1.30	Glaucoma-1004	1.85
5.	Non-G1005	1.39	Glaucoma-1005	1.87
6.	Non-G1006	1.44	Glaucoma-1006	1.80
7.	Non-G1007	1.31	Glaucoma-1007	1.74
8.	Non-G1008	1.47	Glaucoma-1008	1.87
9.	Non-G1009	1.06	Glaucoma-1009	1.78
10.	Non-G1010	1.61	Glaucoma-1010	1.91
11.	Non-G1011	1.61	-	-
12.	Non-G1012	1.35	-	-
13.	---	Mean = 1.3358	---	Mean = 1.8150
14.	---	SD = 0.1833	---	SD = 0.0613

#### IV. CONCLUSION AND FURTHER WORK

The laboratory experimental results are obtained in order to detect neovascular glaucoma results are tabulated in Table1. Table1 reveals that fractal dimension values which ranges from 0.98 to 1.61 for healthy images and for Neovascular glaucoma exceeds the upper limits and maximum 1.99 for retinal images for different threshold values of binary images. The results of the proposed research work emphasizes that there is great potential in the use of fractal dimension for estimating non glaucoma and Neo-vascular glaucoma retinal images. The proposed approach achieved better results compared to the results reported in literature. An extension for this research work could be as follows:

- (1) Instead of consider work retinal image can be considering only neovascularization portion of retina.
- (2) Detection of neovascular glaucoma study can be extended for different types of fractal dimension algorithm.

#### REFERENCE

- [1]. Madhusudhanan Balasubramanian, *et.al.*, "A framework for detecting glaucomatous progression in the optic nerve head of an eye using proper orthogonal decomposition", *IEEE Trans. on Information Technology in Biomedicine*, Vol. 13, No. 5, pp. 781-793, Sept. 2009.
- [2]. Yu-Chang Tzeng, Kuo-Tai Fan, and Kun-Shan Chen, "A Parallel Differential Box-Counting Algorithm Applied to Hyper spectral Image Classification," *IEEE Geoscience And Remote Sensing Letters*, Vol. 9, No. 2, Pp. 272–276, March 2012.
- [3]. Paul Y. Kim, Khan M. Iftikharuddin, *et al.*, "Novel Fractal Feature-Based Multiclass Glaucoma Detection and Progression Prediction," *ieee journal of biomedical and health informatics*, vol. 17, no. 2, pp. 269–276, march 2013
- [4]. Kuo-Kai Shyu, Member, IEEE, Yu-Te Wu, Tzong-Rong Chen, Hui-Yun Chen, Hui-Hsin Hu, Wan-Yuo Guo, "Measuring Complexity of Fetal Cortical Surface from MR Images Using 3D Modified Box-Counting Method," *IEEE Transactions On Instrumentation and Measurement*, Vol. 60, No. 2, Pp. 522–531, February 2011.
- [5]. Friedrich-Alexander, "Retinal image analysis for automated glaucoma risk evaluation," *Proc. of SPIE Vol. 7497 74971C-1*.
- [6]. Paul G. Sanfilippo, *et al.* "A geometric morph metric assessment of the optic cup in glaucoma" P.G. 6 Sanfilippo *et al. / Experimental Eye Research* xxx (2010) 1-10.
- [7]. Sandra Morales, Valery Naranjo, David P´erez, Amparo Navea, Mariano Alcañiz, "Automatic detection of optic disc based on pca and stochastic Watershed," Pp. 2605-2609, Euroship, 2012 – Issn 2076-1465
- [8]. M. Z. Che Azemin, D. K. Kumar, T. Y. Wong, R. Kawasaki, P. Mitchell, and J. J. Wang, "Robust Methodology for Fractal Analysis of the Retinal Vasculature," *IEEE Transactions on Medical Imaging*, Vol. 30, No. 2, Pp.243-250, February 2011.
- [9]. Dharmanna Lamani, Ramegowda, T.C. Manjunath, "Fractal Dimension as Diagnostic Parameter to Detect Glaucoma," *International Journal of Innovations in Engineering and Technology (IJJET)*, Vol. 2 Issue 1, pp.63-69, February 2013.
- [10]. Gopal Datt Joshi, Jayanthi Sivaswamy, S. R. Krishnadas, "Optic Disk and Cup Segmentation from
- [11]. Monocular Colour Retinal Images for Glaucoma Assessment," *ieee transactions on medical imaging*, pp.1-14.2011.
- [12]. Andrew R. H. Swan And Jane A. Garraty, "Image analysis of petrographic textures and fabrics using semi variance," *Mineralogical Magazine*, June 1995, Vol. 59, pp. ANDR189-196.
- [13]. Bo-An Jang, Hyun-Sic Jang & Hyuck-Jin Park, "A new method for determination of joint roughness coefficient," *The Geological Society of London* 2006, pp.1-9.
- [14]. N.C. Kenkel and D.J. Walker, "Fractals in the Biological Sciences," *COENOSIS* 11: pp.77 – 100, 1996.
- [15]. Dharmanna Lamani, Ramegowda, T C Manjunath, "Statistical Analysis of fractal Dimension of Human Eye Images" ,*IFRSA's International Journal Of Computing*, Vol. 2 Issue 1, pp.30-34, January 2012. EW R. H. ANDREW R. H. Swanand
- [16]. Duanwan SHI *et al.*, "Perimeter-area relation and fractal dimension of fracture surface", *J Mater. Sci. Technol.*, Vol. 13, 1997.
- [17]. A. Feroui, M. Messadiġ, I. Hadjidġ, and A. Bessaid. "New segmentation methodology for exudate detection in color fundus images", *Journal of Mechanics in Medicine and Biology* Vol. 13, No. 1 (2013) 1350014 (14 pages)
- [18]. Kittipol Wisaeng *et al.*, "Automatic Optic Disc Detection from Low Contrast Retinal Images" *Applied Mathematical Sciences*, Vol. 6, 2012, no. 103, 5127 – 5136.
- [19]. P. A Burrough, "Fractal dimension of landscapes and other environmental dat", *Nature* vol.294, 19 NOV 1981.
- [20]. Maria Berndt-Schreiber, Anna Baczkowska, "Numerical analysis of fundus eye images in images", *Journal of medical information and Technologies* Vol. &/2004, ISSN 1642-6037.
- [21]. K.Narasimhan, Dr.K.Vijayarekha, "an efficient automated system for glaucoma detection using fundus image", *Journal of Theoretical and Applied Information Technology*, 15th November 2011. Vol. 33, No.1.
- [22]. M. Z. Che Azemin, *et.al.* "Robust Methodology for Fractal Analysis of the Retinal Vasculature", *IEEE Transactions On Medical Imaging*, Vol. 30, No. 2, Pp 243-250, February 2011.
- [23]. Ștefan Țălu, "Characterization of retinal vessel networks in human retinal imagery using quantitative descriptors", *International Journal of the Bioflux Society*, Volume 5, Issue 2, pp 52-57, 2012.
- [24]. Nilanjan Dey, Anamitra Bardhan Roy, Moumita Pal, Achintya Das, "FCM Based Blood Vessel Segmentation Method for Retinal

- Images”, International Journal of Computer Science and Network (IJCSN), ISSN 2277-5420, Volume 1, Issue 3, pp 1-5, June 2012.
- [25]. Ana Salazar-Gonzalez, Djibril Kaba, Yongmin Li and Xiaohui Liu, “Segmentation of Blood Vessels and Optic Disc in Retinal Images”, IEEE Journal of Biomedical and Health Informatics, ISSN 2168-2194, pp 1-14, 2014.
- [26]. Teruhiko Hamanaka, Takayasu Omata, Noriko Akabane, Toshihiro Yajima, and Nobuo Ishida, “Retinal Photocoagulation Density in the Treatment of Neovascular Glaucoma due to Diabetic Retinopathy”, J Clin Exp Ophthalmol, ISSN:2155-9570, pp 1-6, 2012.